
Clinical Quiz

What is the Diagnosis?

SSW **CHENG**, SKL **Ho**, IFM **Lo**

The proband is a 17-year-old boy. He was born full term in Hong Kong to a non-consanguineous Chinese couple. Antenatal checkup was normal. He was referred to genetic clinic for short stature. His height centile drifted away from 25th centile at birth to below 3rd centile at 34 months of age. X-ray showed mildly metaphyseal spraying of distal radius and ulna, slight bowing of distal radial shaft and delayed bone maturation at two years of age (Figure 1 C). On examination at 34 months of age, he had macrocephaly with head circumference of 52.5 cm (above 97th centile). His body weight was 12.5 kg (25th centile) and body height was 84 cm (3 cm <3rd centile). He had frontal bossing, hypertelorism, downslanting palpebral fissures, short nose, lumbar lordosis, normal teeth with tibial bowing

especially left lower limb. He had normal intelligence. His mother had short stature of 144.8 cm (<3rd centile). His mid-parental height was 163.7 cm (10-25th centile). He had mild hearing loss at high frequency without need of hearing aids. Biochemical result showed low serum phosphate level 0.73 mmol/L (1-1.95 mmol/L), normal calcium level, elevated alkaline phosphatase 638 IU/L (104-345IU/L) and reduced tubular resorption of phosphate corrected for glomerular filtration rate (0.5 mmol/L). He was put on phosphate supplement, hydrochlorthiazide and vitamin D since 34 months of age. Later, his renal ultrasound showed nephrocalcinosis at 5.5 years old. His current height was 143 cm at 17-year-old (15 cm <3rd centile). He had regular knee pain and on acupuncture for pain relief.

The clinical quiz was prepared by:

SSW **CHENG**

SKL **Ho**

IFM **Lo**

Clinical Genetic Service, Department of Health, Hong Kong SAR

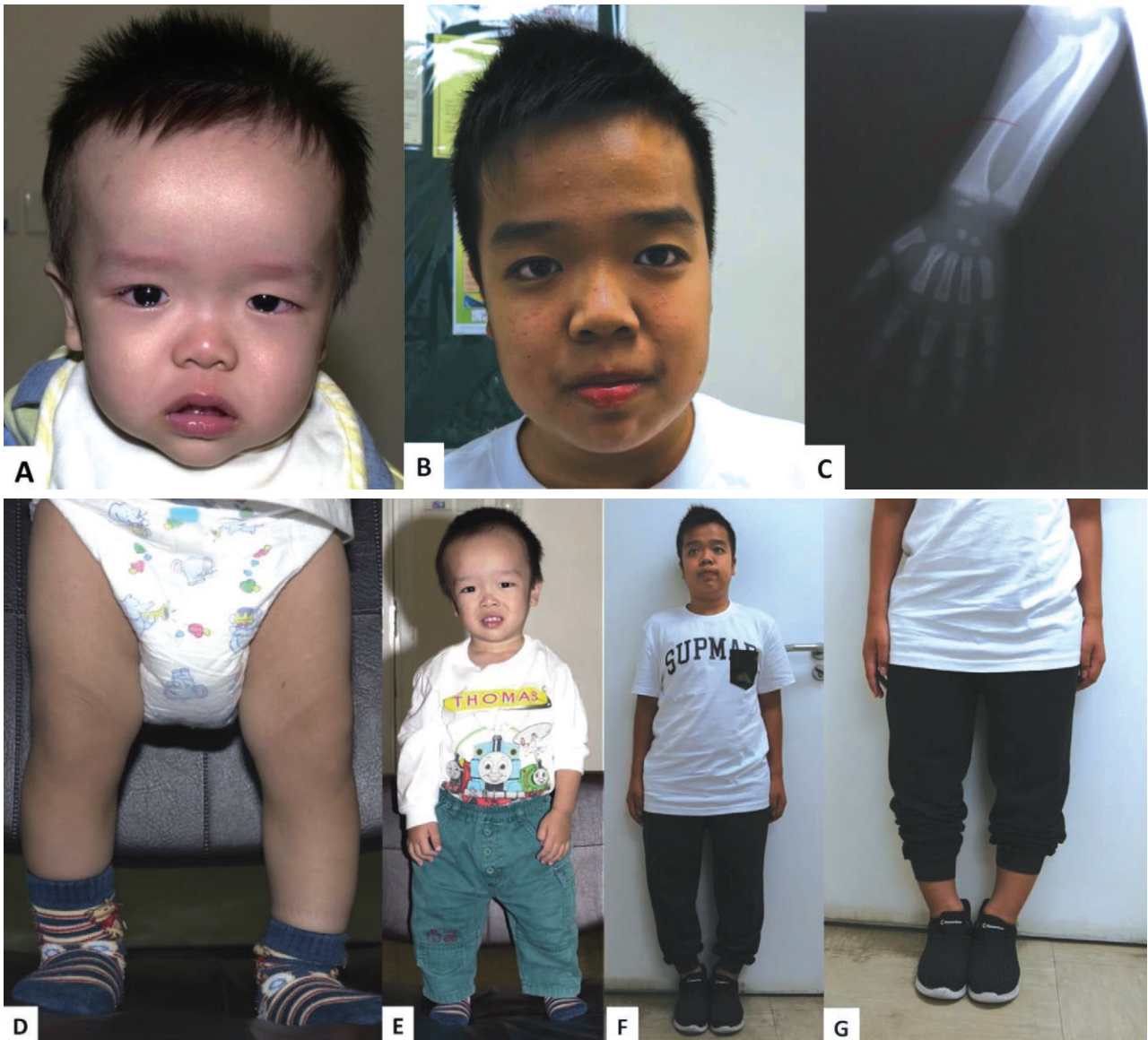


Figure 1 (A) Facial profile of proband at 10 months of age; (B) Facial profile of proband at 17 years of age; (C) X-ray hand of the patient at 2 years of age showing splayed distal radial and ulnar metaphysis with slight bowing of distal radial shaft and delayed bone maturation; (D) Mild bowleg was noted at 2 years of age; (E) Body stature of proband at 2 years of age; (F) Body stature of proband at 17 years of age; (G) Bowlegs were more prominent at 17 years of age (with consents for publication by parents).

Answer to "Clinical Quiz" on Pages 92-95

N.B. The Editors invite contributions of illustrative clinical cases or materials to this section of the journal.