

Letters to the Editor

Concurrent Acute Myocarditis in a Child with Duchenne Muscular Dystrophy

Dear Editor,

The diagnosis of acute myocarditis is made by symptoms, electrocardiogram, elevated biomarkers of myocardial necrosis and echocardiography.¹ Duchenne muscular dystrophy (DMD) is the most common muscular dystrophy in childhood. DMD is characterised by progressive degeneration of the skeletal muscles. Many different patterns of cardiac involvement has been seen in DMD. However acute myocarditis is reported rarely with DMD patients. We want to present a DMD case developed acute myocarditis because of the rarity. A thirteen years old patient who was diagnosed Duchenne muscular dystrophy at the eighteen-month, was admitted to our clinic with chest pain. His pressing style chest pain spread to the left arm. His cardiac examination is normal, there was not additional sound and murmur. In the laboratory tests, white blood cell: 14 800/ μ L, C-reactive protein: 0.53 mg/dL (normal for laboratory: 0-0.5), troponin I: 29.68 ng/mL (normal: 0.00-0.24), troponin T: 2.67 ng/mL (normal: 0.00-0.01), CK-MB: 236 u/L (normal: 0-24), CK: 3582 U/L, BNP: 26.9 pg/mL (normal: 0-100). Electrocardiography showed ventricular extrasystols, straight T wave in V_{2-4} derivations and ST segment elevation >2 mm in D_{2-3} and AVF derivations (Figure 1). QRS axis was 45 degrees, PR: 10 ms, QTc: 420 ms, QRS: 90 ms, heart rate: 94 beats/minute. There was no pathology on echocardiographic examination. Left ventricular ejection fraction and shortening fraction were measured 66% and 36% respectively. Left ventricular end-diastolic dimension was determined 38 mm. He was diagnosed acute myocarditis due to clinical and laboratory findings. Intravenous immunoglobulin treatment was given 400 mg/kg/day for 5 days. The troponin I and CK-MB values

have been decreased after rise during the first 2 days of treatment. The continuous decrease in BNP levels was observed with treatment (Figure 2). The patient was completely free of any symptoms in the third day of the treatment. With resolving complaints, the patient were discharged from hospital on day 6 (Figure 3).

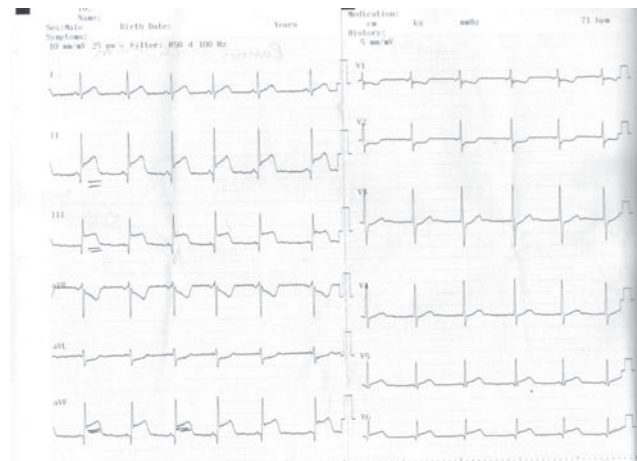


Figure 1 Pretreatment electrocardiography with ST segment elevation.

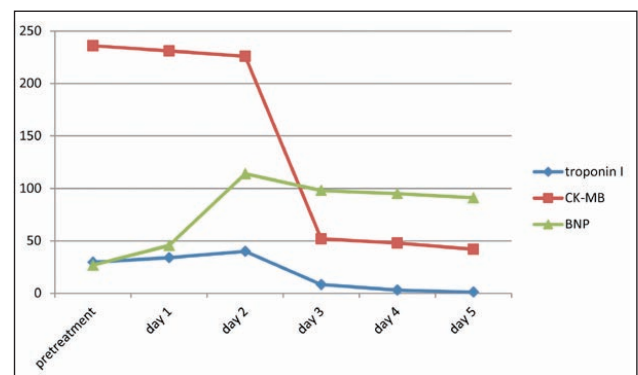


Figure 2 The time-dependent changes of serum biomarkers levels.

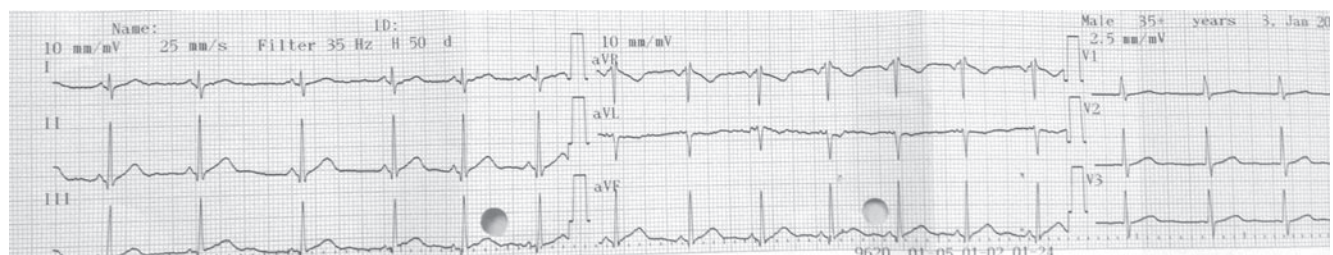


Figure 3 Posttreatment normalised electrocardiography.

Cardiac involvement in DMD are seen quite frequently and is known as a major cause of mortality. Early diastolic dysfunction and focal fibrosis proceed to dilated cardiomyopathy, complicated by heart failure and arrhythmia in most DMD patients. Myocardial defects were observed especially in the inferior wall by using myocard perfusion imaging.² Cardiac disease in DMD is progressive and finally leads to ventricular dysfunction usually accompanied by ventricular dilation.³ Acute myocarditis in DMD patients have been very rarely reported in the literature.⁴ According to previously reports; abnormal dystrophin is a potential susceptibility gene for viral infection of the myocardium and dystrophin deficiency increases enterovirus induced cardiomyopathy.⁵ Our patient was screened for viral and bacterial aetiology of acute myocarditis but we did not find any agent. Although acute myocarditis in DMD patients have been reported very rare, the sudden onset of cardiac symptoms accompanied by deterioration of left ventricular function in young DMD patients should raise the suspicion of possible myocarditis.

Declaration of Interest

None declared

References

1. Iriart X, Vogels G, Lederlin M. Combined computed tomography angiography and cardiac magnetic resonance imaging for diagnosis of acute myocarditis in a child with Duchenne myopathy. *Pediatr Cardiol* 2009;30:1030-1.
2. Zhang L, Liu Z, Hu KY, et al. Early myocardial damage assessment in dystrophinopathies using (99)Tc(m)-MIBI gated myocardial perfusion imaging. *Ther Clin Risk Manag* 2015;10: 1819-27.
3. Mavrogeni S, Markousis-Mavrogenis G, Papavasiliou A, Kolovou G. Cardiac involvement in Duchenne and Becker muscular dystrophy. *World J Cardiol* 2015;7:410-4.
4. Mavrogeni S, Papavassiliou A, Cokkinos DV. Myocarditis in a patient with Duchenne muscular dystrophy detected by cardiovascular magnetic resonance and cardiac biopsy. *Int J Cardiol* 2009;132:123-4.
5. Thrush PT, Flanigan KM, Mendell JR, Raman SV, Daniels CJ, Allen HD. Visual diagnosis: chest pain in a boy with duchenne muscular dystrophy and cardiomyopathy. *Pediatr Rev* 2014;35: 64-7.

A ORGUN
HA GURSU*
II CETIN
E AZAK

Ankara Children's Hematology, Oncology Education
and Research Hospital, Ankara/Turkey

*Correspondence to: Dr HA GURSU